



Contents lists available at ScienceDirect

European Journal of Obstetrics & Gynecology and Reproductive Biology

journal homepage: www.elsevier.com/locate/ejogrb

A new reusable suturing device for vaginal sacrospinous fixation: feasibility and safety study



Talia Friedman^a, Menahem Neuman^{b,c,d}, Yoav Peled^e, Haim Krissi^{e,*}

^a Department of Obstetrics and Gynecology, Chaim Sheba Medical Center, Tel Hashomer, Israel

^b Urogynecology, Department of Obstetrics and Gynecology, Western Galilee Hospital, Israel

^c Faculty of Medicine in the Galilee, Bar Ilan University, Safed, Israel

^d Assuta Medical Center of Tel Aviv and Rishon LeZion, Israel

^e Urogynecology, Department of Obstetrics and Gynecology, Rabin Medical Center, Petach Tikva, Affiliated with Sackler Faculty of Medicine, Tel Aviv University, Tel Aviv, Israel

ARTICLE INFO

Article history:

Received 6 January 2015

Received in revised form 2 June 2015

Accepted 30 June 2015

Keywords:

Pelvic organ prolapse

Sacrospinous ligament fixation

ABSTRACT

Objective: We sought to evaluate the feasibility and safety of SeraPro[®] (Serag-Wiessner, Germany), an innovative reusable suturing device for vaginal sacrospinous ligament fixation.

Study design: We reviewed the electronic files of all women who underwent vaginal sacrospinous ligament fixation with SeraPro[®] for apical pelvic floor prolapse, with or without mesh implant, performed between April 2013 and September 2013. Preoperative demographic, clinical, operative and postoperative data were analyzed. The women were interviewed and examined before the procedure, at one month postoperatively and tele-interviewed again after three months.

Results: Overall, 88 women were included in the study. Fifty-three patients (60.2%) had additional anterior mesh placement, 42 (47.7%) had posterior mesh, and 16 (18.2%) had both anterior and posterior mesh insertion. Five patients (5.7%) had no mesh implant. Sixteen patients (18.2%) had an additional mid-urethral sling for the treatment of stress urinary incontinence. No significant technical difficulty was recorded at the procedures. None of the patients had significant long-term morbidity. The mean 3-month follow-up demonstrated significant anatomical and functional improvement.

Conclusions: The SeraPro[®] reusable suturing device is a feasible and safe tool for sacrospinous ligament fixation during vaginal pelvic floor reconstruction.

© 2015 Elsevier Ireland Ltd. All rights reserved.

Introduction

Pelvic organ prolapse (POP) is a common condition negatively affecting the quality of life of millions of women worldwide with a lifetime prevalence of 3–6% when defined by symptoms and up to 50% when based upon vaginal examination [1]. However, treatment is generally indicated only for women with symptoms of prolapse or associated debilitating conditions (urinary/bowel incontinence, or sexual dysfunction) [2]. The definitive treatment for POP is surgery. Population-based studies report an 11–19% lifetime risk in women to undergo surgery for prolapse or incontinence [3].

Choice of surgical route is the main concern in women who require repair of apical pelvic floor (uterine or vaginal vault prolapse), while isolated repair of anterior or posterior vaginal wall prolapse is typically performed trans-vaginally. Many abdominal (open, laparoscopic and robotic) as well as vaginal techniques have been described to correct apical prolapse [4–8]. Abdominal repair by sacral colpopexy results in a lower rate of recurrence. However, the vaginal approach is related a faster and less painful recovery [9].

One of the most common vaginal techniques is the sacrospinous ligament fixation (SSLF), first described by Richter [10], who used the sacrospinous ligament (SSL) as an anchoring site for vaginal vault suspension. During this procedure, the prolapsed apex is anchored with precisely inserted sutures to the sacrospinous ligament. Prolapse of the anterior or posterior walls of the vagina are repaired at the same time. The main technical obstacles in this technique are the wide and deep trans-vaginal pelvic dissection necessary for proper approach to the SSL and the manipulations for needle passage through the SSL. Some operative facilitating

* Corresponding author at: Department of Obstetrics and Gynecology, Helen Schneider Hospital for Women, Rabin Medical Center, Beilinson Campus, Petach Tikva 49100, Israel. Tel.: +972 3 619 4876; fax: +972 3 937 7585.

E-mail address: haimkr@clalit.org.il (H. Krissi).

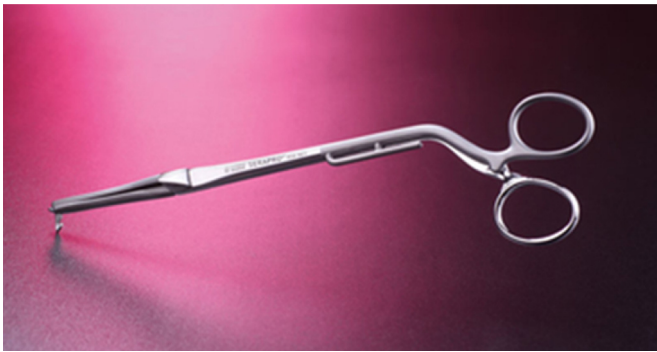


Fig. 1. The SERAPRO[®] RSD-Ney suturing device.




Fig. 2. Tip of the SERAPRO[®] RSD-Ney suturing device.

techniques have been suggested over the years to overcome these problems [11]. Some surgeons elected to implant meshes for the reinforcement of the weakened and herniated pelvic floor. Owing to the recent USA Food and Drug Administration communication about vaginally implanted mesh-related complications [12], many surgeons are reluctant to adopt this method.

The SeraPro[®] stainless steel forceps has a reusable-suturing device designed to facilitate suture placement through the SSL. It necessitates a relatively narrow trans-vaginal dissection toward the SSL, thus potentially reducing the dissection-related complication rate. An added advantage is that the fixation is made by suture only or with a small mesh implant, thus further reducing negative adverse effects as pain and exposure. The instrument has no lumen, or screw-off parts or cavities (Fig. 1), which makes it easy to sterilize. Furthermore, the device can only be dismantled at an angle or twist of more than 90°, which prevents unwanted dismantling during surgery. The tooth and nose proportions prevent excessive deep tissue penetration (Fig. 2). The aim of this study was to assess the surgical feasibility and safety of the SeraPro[®] at trans-vaginal SSLF for apical POP repair.

Materials and methods

This descriptive, retrospective study was based on the experience of a single surgeon (M.N.) who performed a vaginal SSLF procedure using SeraPro[®] in 88 women planned to undergo SSLF for apical prolapse repair between April 2013 and September 2013 in our center.

The study was approved by the local international review board.

Preoperatively, all patients completed a comprehensive questionnaire which included prolapse, urinary, bowel, and sexual symptoms. Office examination and detailed pelvic examination was performed, which involved site-specific vaginal examination in the lithotomy position with a Sim's speculum during a maximal valsalva maneuver. All POP quantification measurements and staging were performed according to the standardized International Continence Society (ICS) scoring system [13]. Each compartment (apical, anterior and posterior) was evaluated for defects in pelvic support. In cases where the vaginal defect was combined with stress incontinence, additional continence surgery was performed, as needed. All patients were interviewed and had a pelvic examination at the end of the first postoperative month and were tele-interviewed again 3 months after surgery.

The surgical procedure

All patients received preoperative prophylactic antibiotics (cefazolin 1 g). Surgery was performed under general anesthesia with the patients in the dorsal lithotomy position. Urethral catheters were not routinely placed at operation. A single

longitudinal anterior or posterior vaginal wall incision was made according to the most damaged compartment, followed by an infra-fascial para-vesical or para-rectal sharp dissection toward the lateral pelvic side-wall, aiming at the ischial spine (IS). This served as a landmark for identifying the SSL. Digital palpation of the IS and SSL guided the device and introduced a No. 0 non-absorbable monofilament suture preferably into the mid-SSL. Once the suture was secured, it was passed through the vaginal wall at the vault without penetrating the vaginal mucosa or through the cervical fibrotic ring if the patient was not hysterectomized before, for suspension. The use of a mesh implant for apical POP reinforcement was performed according to the supportive tissue conditions. This procedure was repeated on the other side. A posterior or anterior vaginal wall repair, if required, was then performed with or without mesh according to the surgeon's impression of the quality of the fascial tissue. After closure of the posterior vaginal wall, the sacrospinous ligament sutures were tied on either side to elevate the vault. In patients with urinary stress incontinence, a mid-urethral sling procedure was performed after the prolapse surgery. All patients were advised to avoid strenuous activities for two months after the procedure.

Outcome measures included the feasibility and safety of the procedure, intraoperative and postoperative complications, prolapse-associated symptoms and POP quantification.

Statistical analysis

A computerized database was created and all clinical data were collected and evaluated. Data analysis was performed with the SPSS software, version 20.0. Student's test was used to compare continuous variables between the groups, and χ^2 test of Fisher's exact test were used for categorical variables. Differences were considered significant when *p* value was less than 0.05.

Results

Overall, 88 women were included in the study. Patient characteristics are described in Table 1. Mean age of patients was 62.8 ± 9.4 years. Fifteen women (17.0%) had undergone previous hysterectomy and 12 (13.6%) had previous POP surgery. During our surgery hysterectomy was not performed in any patient. Anterior mesh was implanted in 53 patients (60.2%), and in 42 (47.7%), posterior mesh. Sixteen patients (18.2%) had both anterior and posterior mesh implants, and 5 patients (5.7%) had no mesh

Table 1
Characteristics of 88 women who underwent sacrospinous fixation with SeraPro[®] forceps for POP.

| Characteristic | Value |
|---|----------------------|
| Age, standard deviation, years (average, range) | 62.80 ± 9.40 (42–85) |
| Body mass index, kg/cm (average, range) | 24.8 ± 4.38 (21–32) |
| No. of deliveries (average, range) | 3.1 ± 1.39 (1–9) |
| Major health problems, n (%) ^a | 39 (44.31%) |
| Previous hysterectomy, n (%) | 15 (17.04%) |
| Previous POP surgery, n (%) | 12 (13.63%) |
| Previous SUI surgery, n (%) | 12 (13.63%) |

POP, pelvic organ prolapse; SUI, stress urinary incontinence.

^a Diabetes and hypertension in 15 women, hypothyroidism in 11, asthma in 2 and cardiac arrhythmia in one patient.**Table 2**
Surgery data on 88 women who underwent sacrospinous fixation with SeraPro[®] forceps for POP.

| Type of surgery | No (%) | No. and type of mesh used (manufacturer) |
|------------------------|------------------------|--|
| Anterior mesh implant | 53 (60.2) ^a | 35 SeraTom (Serag-Wiessner) 13 Proxima (J&J) 5 Prolift (J&J) |
| Posterior mesh implant | 42 (47.7) ^a | 20 SeraTom (Serag-Wiessner) 13 Proxima (J&J) 8 Prolift (J&J) 1 Elevate (AMS) |
| Additional MUS for SUI | 39 (44.3) | 30 TVT-Abbrevio (J&J) 7 TVT-Secure (J&J) 2 SeraSis (Serag-Wiessner) 1 TVT-Exact (J&J) |
| SSLF only without mesh | 5 (5.7) | |

POP, pelvic organ prolapse; MUS, mid-urethral string; SUI, stress urinary incontinence; SSLF, sacrospinous ligament fixation.

^a 12 women had anterior and posterior mesh implant insertion.

implanted at all. A mid-urethral sling was used for the treatment of stress incontinence in 16 patients (18.2%) (Table 2).

The use of SeraPro[®] was feasible in all cases. No significant technical difficulty occurred during the procedure. The needle passage was fruitful in all cases with good hold of the tissue and no intraoperative complications.

Three women had estimated intraoperative bleeding of 200–400 mL, which did not necessitate blood transfusion. An unplanned cystotomy was performed in one woman during the preparatory dissection. This was both diagnosed and sutured during surgery. Ten women (11.4%) had postoperative voiding difficulty; two of them had tension release under anesthesia. Six patients had postoperative fever of unknown origin and two women had postoperative urinary infection; all were treated with broad-spectrum antibiotics (Table 3). Six women had significant postoperative pelvic pain (4–6 on visual analog scale; all resolved up to 3 months after surgery. Two had dyspareunia (one is scheduled for surgery), 2 had symptomatic recurrent prolapse

Table 4
Comparison of main symptoms and vaginal examination.

| Variable | Prior to surgery | Third postoperative month, n (%) | P value |
|---------------------------------|-------------------|----------------------------------|---------|
| Prolapse sensation, n (%) | 88 (100%) | 1 (2.2%) | <0.001 |
| Urgency, n (%) | 49 (55.7%) | 11 (12.5%) | <0.001 |
| Frequency, n (%) | 52 (59.1%) | 11 (12.5%) | <0.001 |
| Nocturia, n (%) | 52 (59.0%) | 16 (18.2%) | <0.001 |
| Ba point, cm, mean ± SD (range) | 2.7 ± 2.8 (–3;10) | –2.6 ± 0.5 (–3;–1) | <0.001 |
| Bp point, cm, mean ± SD (range) | 1.4 ± 2.5 (–3;–1) | –2.6 ± 0.5 (–3;–1) | <0.001 |
| C point, cm, mean ± SD (range) | 0.6 ± 3.1 (–5;12) | –6.2 ± 1.0 (–7;–1) | <0.001 |

Statistical tests:

For categorical variables (urgency, frequency), the McNemar test was used.

For continuous variables (nocturia, Ba, Bp, C) the Wilcoxon signed rank test was used.

Table 3
Complications of 88 women who underwent sacrospinous fixation with SeraPro[®] forceps for POP.

| Complication | No. (%) | Remarks |
|-------------------------------|------------|--|
| Voiding difficulty | 10 (11.4%) | Resolved spontaneously after catheterization in 8 Two needed tension release |
| Intraoperative bleeding | 3 (3.4%) | No blood transfusion requested |
| Fever | 6 (6.8%) | Treated with antibiotics |
| UTI | 2 (2.3%) | Treated with antibiotics |
| Inadvertent cystectomy | 1 (1.1%) | Sutured during surgery |
| Pain ^a | 6 (6.8%) | All symptoms resolved up to 3 months after operation |
| Dyspareunia | 2 (2.3%) | One patient was scheduled for surgery |
| De-novo SUI | 3 (3.4%) | Two patients were scheduled for surgery |
| Persistent overactive bladder | 7 (7.9%) | Treated with anticholinergic drugs |
| Recurrent prolapse | 2 (2.3%) | C point = 0 |
| Patient dissatisfaction | 5 (5.7%) | 1 over-active bladder 1 dyspareunia 1 vaginal pain 1 recurrent UTI 1 voiding difficulty and successive surgery |

SUI, stress urinary incontinence; UTI, urinary tract infection.

^a Areas of pain were anal (n=3), sacral (n=2) and thigh (n=1).

(non-desires to be reported). Three patients had de-novo USI; 2 were referred for mid-urethral sling surgery.

A 3-month postoperative follow-up demonstrated significant improvement with the preoperative anatomical and functional parameters (Table 4). Among other beneficial quality-of-life improvements, a statistically significant decrease in urgency frequency and nocturia was noted ($p < 0.001$).

Comments

For many surgeons, the vagina is the natural orifice for POP reconstruction, and this approach is commonly used for apical prolapse repair surgery, using the SSLF for anchorage. One major disadvantage for vaginal SSLF is the wide and deep dissection needed to approach the SSL. Another disadvantage is that many of the previously used suturing or anchoring devices are disposable, thus costly, and require deep pelvic manipulation. Such surgical steps increase the risk of intra-operative bleeding and pelvic organ injury [11].

The SeraPro[®] suturing device used for the surgical treatment of apical POP is a safe, feasible and efficient vaginal SSLF. This is particularly important given the complexities involved in the correction of the apical compartment during POP reconstruction. The SeraPro[®] is reusable, and therefore more economical, and sutures to the SSL can be delivered placed via a narrow vaginal

incision, and can be used with or without mesh implant. It avoids the use of synthetic anchors.

Several studies have previously reported that the use of small devices requires less surgical dissection, thus reducing surgery time and complications.

Pollak et al. [11] compared the complications of three techniques for SSLF: (1) the standard needle driver with direct visualization; (2) the Deschamps ligature carrier by palpation; and (3) the Miya hook ligature carrier by palpation. They observed that sutures passed through the SSL under direct conduction resulted in less intra- and postoperative complications. In our study, the SeraPro[®] device delivered sutures via a narrow vaginal incision under direct conduction with no intraoperative complications. Moreover, the surgically-related complications in our study were relatively mild and few, similar to other studies.

Manning et al. [14] examined the vascular safety of six devices currently used for SSLF using cadaveric examination. They noted that the vascular anatomy behind the sacrospinous ligament is enormously variable and that the SSL may be thin in the elderly. For vascular safety, the ideal device enfolds but does not penetrate behind the ligament. The i stitch[®] was seen to penetrate coccygeal branches of inferior gluteal artery. The Capiro[®], Caspari[™] and Endostitch[®] remained confined within all **ligaments/vessels?**, including thin ligaments. The Miya[®] hook and Deschamp[®] impinged upon but deflected vessels behind thin ligaments. Others mentioned that the Capiro[™] suture capturing device simplified the procedure, and reduced the operative time and blood loss when compared to the traditional technique [15,16].

An objective anatomic cure was noted in 94.5% of patients in a study by Mothes et al. [17], and significant improvement of all prolapse symptoms after bilateral minimal tension sacrospinous fixation. Only 5.5% of the patients in their report experienced postoperative urinary tract infection. No other complications requiring medical or surgical intervention were reported.

The strength of our study was the large cohort and the performance of the operations by one surgeon. The limitations were its retrospective design which limited the retrieved data, the use of a non-validated questionnaire and the concurrent performance of anterior and posterior mesh procedures, which might confound the findings. The purpose of the study was not to evaluate the cure rate of the SSLF surgery but the safety and the efficacy of the SeraPro[®] device, so the short follow-up is irrelevant for this study.

In conclusion, the use of SeraPro[®] suturing device for vaginal SSLF for the correction of apical POP is easy to use and safe. Randomized clinical trials with objective surgical criteria are required to compare different vaginal suturing devices.

Conflict of interest

M.N. is a consultant for Serag-Wiessner. The other authors declare no conflict of interest.

Funding

No funding was received for this work.

References

- [1] Barber MD, Maher C. Epidemiology and outcome assessment of pelvic organ prolapse. *Int Urogynecol J* 2013;24:1783–90.
- [2] Smith FJ, Holman CD, Moorin RE, Tsokos N. Lifetime risk of undergoing surgery for pelvic organ prolapse. *Obstet Gynecol* 2010;116:1096–100.
- [3] Olsen AL, Smith VJ, Bergstrom JO, Colling JC, Clark AL. Epidemiology of surgically managed pelvic organ prolapse and urinary incontinence. *Obstet Gynecol* 1997;89:501–6.
- [4] Arbel R, Lavy Y. Vaginal vault prolapse: choice of operation. *Best Pract Res Clin Obstet Gynaecol* 2005;19:959–77.
- [5] Pulliam SJ, Weinstein MM, Wakamatsu MM. Minimally invasive apical sacropexy: a retrospective review of laparoscopic and robotic operating room experiences. *Female Pelvic Med Reconstr Surg* 2012;18:122–6.
- [6] Paraiso MF, Ballard LA, Walters MD, Lee JC, Mitchinson AR. Pelvic support defects and visceral and sexual function in women treated with sacro-spinous ligament suspension and pelvic reconstruction. *Am J Obstet Gynecol* 1996;175:1423–31.
- [7] Lovatsis D, Drutz H. Vaginal surgical approach to vaginal vault prolapse: considerations of anatomic correction and safety. *Curr Opin Obstet Gynecol* 2003;15:435–7.
- [8] Yazdany T, Wong K, Bhatia NN. Sacrospinous ligament fixation for pelvic organ prolapse in the era of vaginal mesh kits. *Curr Opin Obstet Gynecol* 2011;23:391–5.
- [9] Maher C, Feiner B, Baessler K, Schmid C. Surgical management of pelvic organ prolapse in women. *Cochrane Database Syst Rev* 2013;4C: CD004014.
- [10] Richter K. The surgical anatomy of the vaginaefixatio sacrospinalis vaginalis. A contribution to the surgical treatment of vaginal blind pouch prolapse. *Geburtshilfe Frauenheilkd* 1968;28:321–7 [in German].
- [11] Pollak J, Takacs P, Medina C. Complications of three sacro-spinous ligament fixation techniques. *Int J Gynaecol Obstet* 2007;99:18–22.
- [12] Food and Drug Administration. FDA Safety Communication: update on serious complications associated with transvaginal placement of surgical mesh for pelvic organ prolapse; 2011, <http://www.fda.gov/MedicalDevices/Safety/AlertandNotices/umc262435.htm> [accessed 15.06.14].
- [13] Bump RC, Mattiasson A, Bø K, et al. The standardization of terminology of female pelvic organ prolapse and pelvic floor dysfunction. *Am J Obstet Gynecol* 1996;175:10–7.
- [14] Manning JA, Arnold P. A review of six sacrospinous suture devices. *Aust N Z J Obstet Gynaecol* 2014;54:558–63.
- [15] Leone Roberti Maggiore U, Alessandri F, Remorgida V, Venturini PL, Ferrero S. Vaginal sacrospinous colpopexy using the Capiro suture-capturing device versus traditional technique: feasibility and outcome. *Arch Gynecol Obstet* 2013;287:267–74.
- [16] Vaudano G, Gatti M. Correction of vaginal vault prolapse using Capiro[™] suture capturing device: our experience. *Minerva Ginecol* 2015;67:103–11.
- [17] Mothes AR, Wanzke L, Radosa MP, Runnebaum IB. Bilateral minimal tension sacrospinous fixation in pelvic organ prolapse: an observational study. *Eur J Obstet Gynecol Reprod Biol* 2015;188:1–5.